

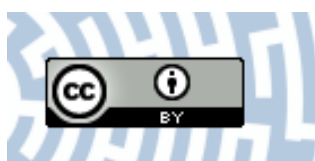


You have downloaded a document from
RE-BUS
repository of the University of Silesia in Katowice

Title: The applications of infrared thermography in surgical removal of retained teeth effects assessment

Author: Teresa Kasprzyk-Kucewicz, Armand Cholewka, Karolina Bałamut, Patryk Kownacki, Natalia Kaszuba, Michał Kaszuba i in.

Citation style: Kasprzyk-Kucewicz Teresa, Cholewka Armand, Bałamut Karolina, Kownacki Patryk, Kaszuba Natalia, Kaszuba Michał i in. (2020). The applications of infrared thermography in surgical removal of retained teeth effects assessment. "Journal of Thermal Analysis and Calorimetry" 2020 (article in press), doi 10.1007/s10973-020-09457-6



Uznanie autorstwa - Licencja ta pozwala na kopiowanie, zmienianie, rozprowadzanie, przedstawianie i wykonywanie utworu jedynie pod warunkiem oznaczenia autorstwa.



UNIwersYTET ŚLĄSKI
W KATOWICACH



Biblioteka
Uniwersytetu Śląskiego



Ministerstwo Nauki
i Szkolnictwa Wyższego



The applications of infrared thermography in surgical removal of retained teeth effects assessment

Teresa Kasprzyk-Kucewicz¹ · Armand Cholewka¹ · Karolina Bałamut¹ · Patryk Kownacki² · Natalia Kaszuba³ · Michał Kaszuba³ · Agata Stanek⁴ · Karolina Sieron⁵ · Jiri Stransky⁶ · Adam Pasz⁶ · Tadeusz Morawiec²

Received: 10 July 2019 / Accepted: 15 February 2020
© The Author(s) 2020

Abstract

At the beginning, applications of thermal imaging in dentistry were focused mostly on the assessment of thermal effects during filling cavities, laser treatment and inflammation of periodontal tissues. The biggest problem in thermal imaging was limiting access and rapid change of humidity when the mouth opens during measurements. However, nowadays thermal map of body surface is correlated with inflammatory state changing inner mouth. The aim of this study was to assess the suitability of thermal imaging to localize the inflammation and monitor treatment effects after surgical removal of third retained molar teeth. The cohort consisted of 27 patients with referral for the surgical extraction of the third retained molar. Thermal imaging of the sagittal face was performed before and after the procedure and on the first, fourth and seventh day after the extraction. Obtained thermal maps are correlated with the third molar teeth inflammation location. Moreover, the changes of temperature in the area of both the tooth and the cheek correspond to the mechanisms of wound healing described in the literature. Obtained results were not only qualitative but also quantitative what was confirmed by statistically significant difference. It seems that thermal imaging, which is a noninvasive method, can be used to monitor treatment processes after surgical procedures, as well as on the location of inflammation.

Keywords Thermography · Dentistry · Retained teeth · Infrared radiation

Introduction

Infrared thermography is a field of science based on the detection of infrared radiation from an object at temperature above absolute zero. The energy recorded by a detector is processed to create a pixel map in which temperature values are defined using a color scale [1, 2]. Thermography has a wide range of applications, and it is used by the industry, the power and construction sectors, as well as medicine. Medical applications are based on the use of thermography in oncology, allergology, dermatology, physiotherapy, sports medicine, or even dentistry [2–6].

The connection between the body temperature and tissue metabolism allows thermal imaging to be used to assess disease processes, injuries and inflammatory processes. It also allows to follow-up and monitoring the therapeutic procedures [7, 8].

The first attempts to use thermal imaging in dentistry took place as late as at the end of the twentieth century. In dentistry, the location of the monitored area is rather specific; therefore, limitations resulting from accessibility or

✉ Teresa Kasprzyk-Kucewicz
ter.kasprzyk@gmail.com

¹ Faculty of Science and Technology, University of Silesia in Katowice, Katowice, Poland

² Dental Surgery Department at the Chair and Clinic of Maxillofacial Surgery and Dental Surgery, School of Medicine with the Division of Dentistry in Zabrze, Medical University of Silesia in Katowice, Bytom, Poland

³ Institute of Dentistry in Katowice, Katowice, Poland

⁴ Chair and Clinical Department of Internal Medicine, Angiology and Physical Medicine, Medical University of Silesia in Katowice, Bytom, Poland

⁵ Chair of Physiotherapy, Department of Physical Medicine, Faculty of Health Sciences, Medical University of Silesia in Katowice, Katowice, Poland

⁶ Department of Oral and Maxillofacial Surgery, University Hospital Ostrava, Ostrava, Czech Republic

sudden changes in moisture levels should be considered during *in vivo* measurements. To date, measurements mainly concern the evaluation of thermal effects during the filling of lesions with light-cured materials (*in vivo* and *in vitro*), evaluation of dentistry laser procedures, diagnostics of periodontal inflammatory processes, or diseases of the temporomandibular joint [8–10].

Currently, thermography is increasingly often used not only to evaluate changes in the temperature inside the oral cavity, but attempts are primarily made to correlate the soft tissue temperatures on the body surface with the condition of tissues inside the oral cavity, to predict the results of the procedures performed.

Therefore, the aim of this study was to evaluate the effects of surgical extraction of impacted third molars. The current popularity of procedures of this type creates a question whether thermography, as a noninvasive imaging technique which is relatively simple to use, can be useful in the evaluation of an inflammation area created by the retention of impacted third molars. The study also focuses on the evaluation of changes in tissue metabolism related to the healing of a wound after a surgical procedure.

Temperature of a living body and the thermoregulation mechanism

Living processes occurring in the body are strictly connected to thermal homeostasis. Thermal balance is responsible for the normal functioning of skeletal muscles, the heart and the nervous system [11]. There is a general opinion that an optimum body core temperature is 37.0 ± 1.0 °C; however, publications focusing on this subject specify values of 36.8 ± 0.5 °C [12–14]. It is known that in conditions of thermodynamic equilibrium the body core temperature is maintained at a constant level; however, disruptions in the form of stress, physical effort, or disease may lead to its fluctuations [15].

In turn, body surface tissues, such as the most external tissue—the skin, are greatly susceptible to changes in the ambient temperature, and it is stated that in normal conditions the average temperature of the skin ranges from 32 to 35 °C [13]. As thermal homeostasis is a precondition for the functioning of a living organism, maintaining its sustainable balance requires the production of thermal energy (thermogenesis) on the one hand, and removal of excess heat (thermolysis) on the other [11]. Heat loss is achieved by radiation, convection, sweat evaporation, as well as through the respiratory and excretory systems, while thermogenesis depends on metabolism, the work of skeletal muscles and the gastrointestinal function [16]. All processes are controlled through the hypothalamic center in the brain, controlling fluctuations in the skin and internal organ temperatures via a network of thermal receptors. The temperature is stabilized

by the initiation of relevant thermoregulation processes. Thermal receptors then switch to a thermometric state, and the body does not feel either cold or heat. Skin receptors reach their resting activity in the range from 33 to 34 °C, while the neutral point in the hypothalamus is reached at a value of 37 °C [11, 17].

Metabolic processes are considered to be the main source of thermal energy in the body, and according to the literature data, nearly 60% of total energy is used to generate heat [11, 13]. Due to such considerable production of thermal energy, excess heat must be removed to protect the body against overheating. In normal conditions at rest, energy is lost through radiation—about 54–60%, convection and conductivity—25%, sweat evaporation—7% and breathing—14% [13]. Metabolism is a factor necessary to sustain life; however, it closely depends on the physiology of the human body and its condition. Factors such as illness, pregnancy or physical activity have a significant impact on metabolism levels, when compared to a rested body in normal conditions.

It should be noted that the development of a disorder in the form of local inflammation also results in a local increase in metabolism [11, 13, 18].

Impacted teeth in dental surgery

Dental surgery is a separate specialization involving areas of the oral cavity, maxillary bones and surrounding tissues. Specialist procedures in this field include surgical extraction of milk, permanent and impacted teeth, implant surgery, plastic surgery of the alveolar process, or apical resection [19, 20].

An retained tooth is defined as a fully developed tooth that has failed to erupt physiologically and remained, fully or partially, retained in jaw or mandible bones. Factors influencing the development of an impacted tooth include cysts, injuries, bone infections, neoplastic lesions, hormone imbalance, or development disorders. Impacted teeth frequently do not cause any pain and are diagnosed due to the failure of the tooth to erupt with a simultaneous protrusion of the alveolar process. A doctor diagnoses this condition using radiography, taking intraoral periapical and bite-wing X-rays. [19–21].

In the retained tooth extraction procedure, the difficulty is related to the tooth location and place (upper or lower jaw). In general, the procedure starts with anesthesia, and then an incision is made in mucosa and periosteum, followed by the detachment of a mucoperiosteal flap with a scraper. In the next step, which aims to reveal the tooth crown and root, the bone is removed in layers with a drill, and then the tooth is extracted (either as a whole or in fragments). The procedure ends with the placing of the knotted suture for the next 8–10 days [19, 20, 22].

The procedure is followed by a wound healing process. It is a complex process, in which the alveolar crest is completely rebuilt only 10 weeks after the procedure. Immediately after the procedure, the wound fills with blood, and a thrombus is formed. Substances present in the thrombus should stimulate the functioning of mesenchymal cells, which cause an increase in the activity of inflammatory cells. The phagocytosis is initiated, and the bacteria or dead tissues are removed. The remaining fragments are differentiated into various cells, including fibroblasts or osteoblasts, which are aimed at fibers formation in the extracellular matrix [23–25]. Next, new blood vessels are formed, and the resorption of the bone is initiated caused by the osteoclasts appearance. This lead to the formation of a new bone. On day 4 or 5 after the extraction, epithelial cells start to proliferate. On day 7, the granulation tissue develops, which is an accumulation of fibroblasts and myofibroblasts [25].

The real wound healing process starts with the formation of osteoid, beginning in the periapical area up to the edge of the hollow. The transformation of osteoblasts into osteocytes results in the formation of bone trabeculae, and the mineralization process occurs in the formed osteoid. At the next stage of the repair process, osteon is formed, and a bone plate develops. After about 2 weeks from the procedure, a fibrous bone is formed in the extraction area, which is transformed into woven, and then into lamellar bone. In the 8 week, the woven bone is resorbed, and then the new bone is created, finally transformed into compact bone [23–26].

The extraction of the retained third molar described above, together with associated wound healing processes may cause pain and be a source of inflammation. Thus, they may be associated with a local increase in metabolism leading to local changes in the temperature [8, 27, 28].

The inflammation developed in this way, as well as its extent and dynamics, can be monitored and evaluated by thermal imaging. By using a study protocol developed for medical applications of the thermography, and knowing physical parameters of the environment and of the examined tissues (moisture content, emission index), an initial parametric evaluation of metabolic changes and their dynamics is possible.

Materials and methods

Twenty-seven patients, age 27–40, participated in the study. The patients were referred for surgical excision of the impacted third molar. Each time, on the procedure day and during follow-up visits (days 1, 4 and 7 after the procedure), a survey verifying guidelines qualifying patients for thermographic examination was conducted, which included information concerning the use of stimulants (alcohol, cigarettes), performance of physical exercises, exposure

to sunlight or UV radiation, or use of analgesics and other medicines. The examinations were performed at a health and dental clinic, ComfortDent, in Katowice, in a room meeting standards for the performance of thermographic examinations. The temperature and the moisture content in the test room were monitored and maintained at a constant level of 19 ± 1 °C and $43 \pm 5\%$, respectively.

Thermal imaging was performed on the day of the procedure, i.e., before and after excision of the impacted third molar, and on Day 1, 4 and 7 after the procedure. Thermal imaging was performed once the patient had acclimatized to ambient temperature, which took 20 ± 5 min.

Imaging was performed with a thermal camera, FLIR Systems E60, equipped with a microbolometric detector being an FPA matrix detector of 320×240 pixels. The sensitivity of the camera used is 0.05 K. The camera was installed on a tripod placed 0.9 ± 0.1 m from a patient. The imaging covered the sagittal plane of the face on the side of the procedure, as well as the control (healthy) side.

The thermograms were analyzed in the ThermaCAM Researcher Pro 2.10 application, during which selected areas affected by the disease were marked, i.e., the buccal area AR01, and the third molar area, AR02 (Fig. 1). The temperature values obtained were analyzed with Microsoft Excel 2018 and Statistica Soft 12 applications.

The mean temperature for chosen regions of interest (ROI) was always calculated as an average of all pixels in marked area.

The relationship between mean temperature values between measurements was analyzed with a nonparametric equivalent of the Student's *t* test for related samples, i.e., the Wilcoxon's test. To determine statistically significant differences, a *p* parameter value lower than or equal to 0.05 was assumed. In this analysis, a comparative model for adjacent measurements was assumed, i.e., T_i versus $T_{(i+1)}$ and T_i versus $T_{(i+2)}$; furthermore, measurements on day 7 after the procedure were compared against measurements before and after the procedure, i.e., $T_{\text{Day 7}}$ versus T_{before} and $T_{\text{Day 7}}$ versus T_{after} . Table 1 shows results where the *p* value was below 0.05 for the buccal area and for the area of the extracted tooth.

Results and analysis

Figure 1 shows thermal images for a representative patient who underwent surgical extraction of the upper third molar, before, immediately after, and on Day 1 and Day 7 after the procedure. Additionally, Fig. 1 presents ROI's used in the analysis, AR01—buccal area, AR02—tooth area.

Changes in the buccal surface temperature in response to the surgical intervention are clearly visible with a visual examination. Furthermore, it can be seen that before the

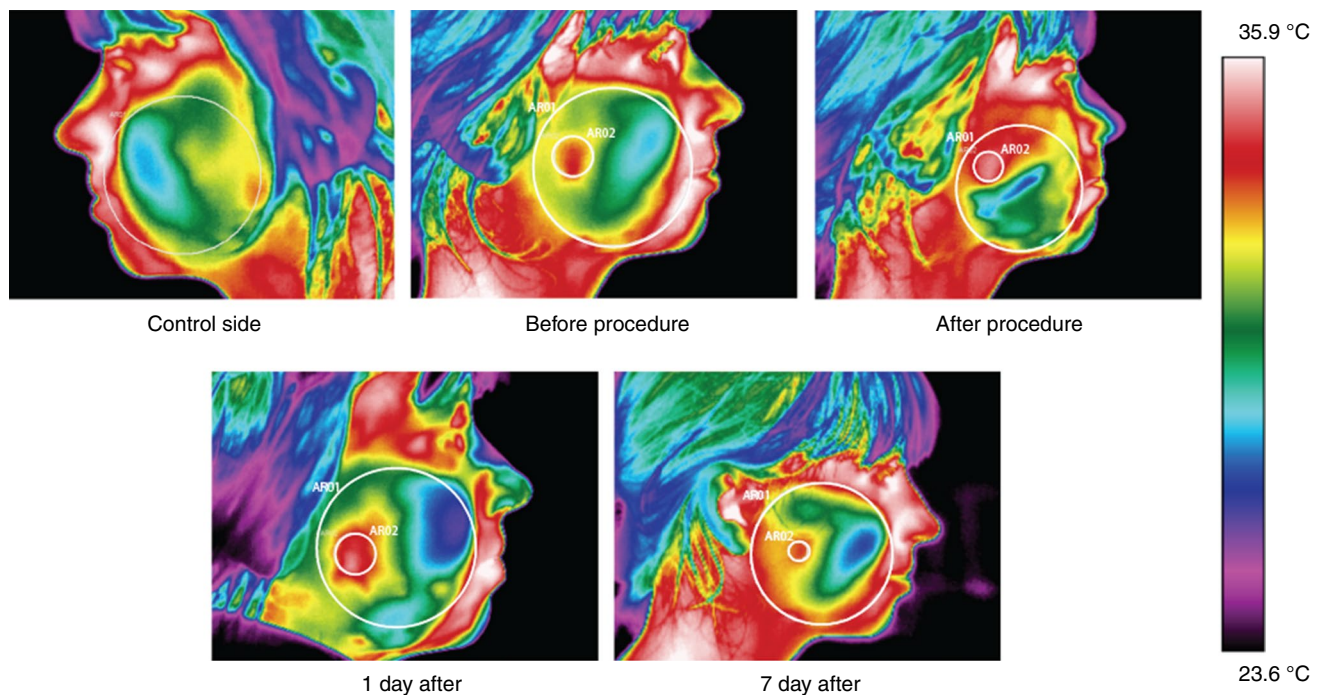


Fig. 1 Thermal images showing changes in the temperature on the buccal surface on the side of the performed procedure: before, immediately after, and on Day 1 and Day 7 after the procedure, and a thermogram of the control side, where AR01—buccal area, AR02—tooth area

Table 1 Statistically significant results of a comparative analysis for mean temperatures of the buccal area and the third molar performed with the Wilcoxon test, where dT is the mean difference of temperature and p value—the value of probability

Pair of variables	Tooth area		Buccal area	
	dT	p value	dT	p value
$T_{\text{after}}/^{\circ}\text{C} - T_{\text{Day 4}}/^{\circ}\text{C}$	2.8	0.005	2.8	0.005
$T_{\text{Day 7}}/^{\circ}\text{C} - T_{\text{before}}/^{\circ}\text{C}$	2.5	0.012	2.4	0.015
$T_{\text{Day 7}}/^{\circ}\text{C} - T_{\text{after}}/^{\circ}\text{C}$	2.1	0.038	2.3	0.024

Differences with a p factor less than 0.05 were recognized as significant

procedure, the area of the impacted third molar is characterized by higher temperature, and this may imply inflammation in this area.

Figure 2 shows a change in the mean temperature of the tooth area surface in time (a) and dynamics of changes in the temperature difference, $dT_{(\text{tooth-cheek})} = T_{\text{tooth}} - T_{\text{cheek}}$ (b).

When analyzing data in Fig. 2, it can be seen that before the procedure, the area of the third molar has higher temperatures than the buccal area. Retained teeth are frequently associated with inflammatory states, infections and pain, which may contribute to an increase in the temperature in this area. After the procedure, the difference between mean temperatures of these two areas decreases. This may be an effect of steps taken to remove the impacted tooth, as well

as medicines and anesthetic used. From day 1 to day 4 after the procedure, an increase in the temperature values is seen in the tooth area, versus the buccal area, and this is possibly caused by the initiation of repair processes and an increase in the metabolism of tissues subjected to surgical intervention. It should also be emphasized that immediately after tooth extraction, the alveolus is filled with blood and a thrombus is formed, and this also influences an increase in the temperature in this area.

An analysis of changes in the temperature in the impacted tooth area shown in Fig. 2a clearly indicates that between day 1 and day 4 the temperature showed a tendency to decrease. The temperature drops from 34.4 to 32.9 °C. This mean temperature change by 1.5 °C may be caused by the initiation of repair processes in the tissue. However, on day 7 after the procedure, an increase in temperature can be seen versus day 4 from 32.4 to 33.0 °C, however, without significant level of p factor. By correlating temperature values with the literature data, it seems that this increase was possibly caused by the formation of granulation tissue within the extraction site, which is distinguished by a significant number of vascular structures supplying that area with nutrients and oxygen [23, 24, 26, 29].

In accordance with the results of the comparative analysis presented in Table 1, it can be clearly seen that the significant changes appear in fourth and seventh day after the procedure relative to temperature after surgery. Processes occurring in the body after surgical intervention are protracted

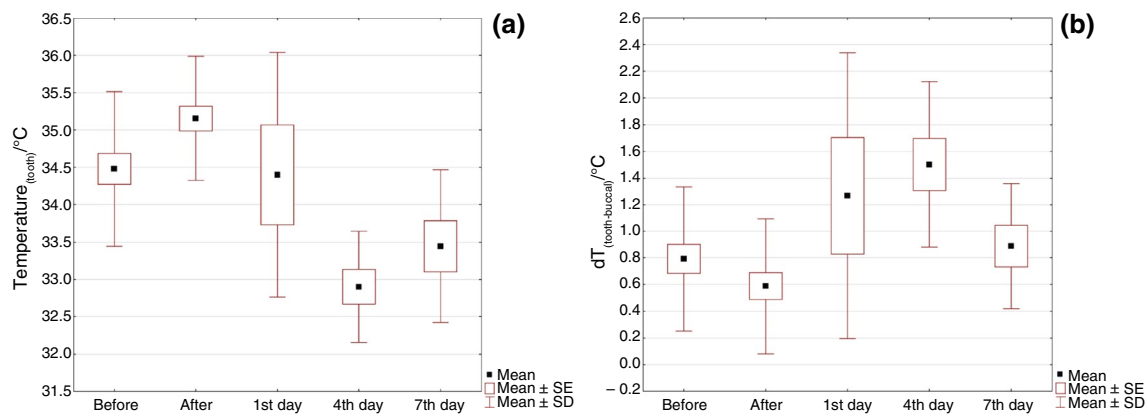


Fig. 2 Time dependence of changes in the mean temperature: **a** changes in the average tooth surface temperature; and **b** changes in temperature difference, $dT_{(tooth-cheek)}$

and not as dynamic as it was expected. The occurrence of a statistically significant change in the temperature only after 4 days after the procedure reflects a gradual recovery of the body. Based on the literature data, between fourth and fifth day the proliferation of epithelial cells begins in soft tissues. Before that the phagocytosis is initiated and the neoangiogenesis starts, so the network of blood vessels grows. Then, bone resorption occurs as a result of osteoclast and a new bone is created [25]. It seems that the decreasing of tooth area temperature from value 34.4 °C at day first to 32.4 °C at day fourth may be related to the end of phagocytosis process. In terms of homeostasis restoration, the fact of obtaining statistically significant differences for comparison of the temperature on Day 7 after the procedure versus the temperatures before and after the procedure appears to be significant. The p factor value is higher than for comparison between T_{after} and $T_{Day 4}$; however, it is also less than 0.05. On the seventh day, granulation tissue with a significant number of vascular structures is formed, which is an accumulation of fibroblasts and myofibroblasts [25]. The presence of vascular structures and fibroblasts may increase the local metabolism and consequently lead to a temperature increase of 0.6 °C between fourth and seventh day after the procedure. Differences demonstrated in this case show that the healing process progresses in time, and the measurements performed with a thermal camera indirectly reflect changes in tissue metabolism [28].

Additionally, for a comparative analysis of measurements before and after the procedure in the impacted tooth area, the Student's t test for related samples was performed, and its results are shown in Fig. 3.

When analyzing data included in Fig. 3, it can be noticed that the mean temperature increased after the extraction of the impacted third molar. This, possibly, is a result of intervention in this area, as well as the previously mentioned filling of the alveolus with blood and the

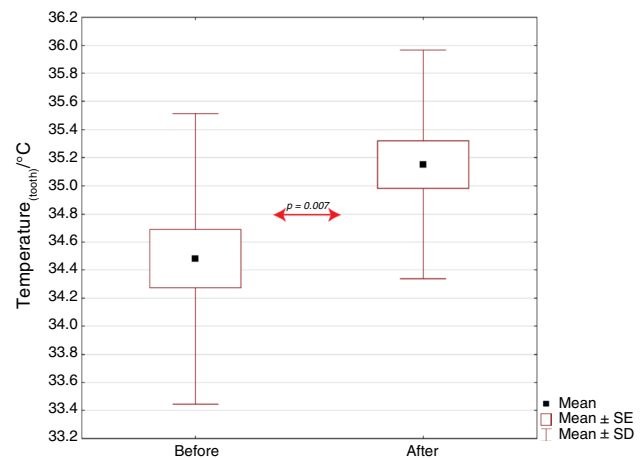


Fig. 3 Comparative analysis of mean temperature values before and after the procedure for the impacted tooth area versus a value of statistical significance for the performed Student's t test. Statistically significant results for $p < 0.05$

formation of a thrombus, which contains numerous substances responsible for the cleaning of the post-extraction wound [20, 23, 24, 28]. The performed Student's t test for related samples shows a statistically significant difference, and this was an expected result proving that the thermal analysis of the third molar area is a useful tool during the surgical extraction procedure.

It is worth noting that the imaging was performed for the external face surface, i.e., for the skin. This way, a problem with accessing third molars, as well as a problem of dynamic changes in moisture levels in the oral cavity, disrupting the results, was eliminated. Verifying this study in terms of the skin imaging, obtaining results already visually reflecting dynamics in temperature changes (results shown in Fig. 1), as well as statistically significant results (results shown in Table 1 and Fig. 3) would indicate the inflammation intensity

for impacted teeth, and a scale of repair mechanisms occurring in the body after the procedure.

Conclusions

On the basis of the results presented above, a hypothesis can be proposed that thermal imaging is a useful tool not only for the evaluation of surgical procedures, but also for the localization of inflammatory processes in periodontal tissues.

Thermal imaging can be used to diagnose pathological conditions caused by tooth retention because the thermal map of the examined surface shows areas of increased metabolism in the form of higher temperature. The presented analysis of temperature distribution dynamics indicates a correlation between changes in the temperature and repair processes occurring in the body.

Changes in the thermal map resulting from dynamics of the occurring processes, as well as their extent, can be monitored and evaluated using thermal imaging, and an initial parametric evaluation of metabolic changes, and their dynamics is possible using a research protocol developed for medical applications of thermography, and knowing physical parameters of the environment and the examined tissues (moisture content, emission index).

Open Access This article is licensed under a Creative Commons Attribution 4.0 International License, which permits use, sharing, adaptation, distribution and reproduction in any medium or format, as long as you give appropriate credit to the original author(s) and the source, provide a link to the Creative Commons licence, and indicate if changes were made. The images or other third party material in this article are included in the article's Creative Commons licence, unless indicated otherwise in a credit line to the material. If material is not included in the article's Creative Commons licence and your intended use is not permitted by statutory regulation or exceeds the permitted use, you will need to obtain permission directly from the copyright holder. To view a copy of this licence, visit <http://creativecommons.org/licenses/by/4.0/>.

References

- Więcek B, De Mey G. Termowizja w podcierwieniu, podstawy i zastosowania. Warsaw: Wydawnictwo PAK; 2011.
- Minkina W. Pomiary termowizyjne – przyrządy i metody. Częstochowa: Wydawnictwo Politechniki Częstochowskiej; 2004.
- Cholewka A, Kasprzyk T, Stanek A, Sieroń-Stołyńska K, Drzazga Z. May thermal imaging be useful in cyclist endurance tests? *J Therm Anal Calorim.* 2015. <https://doi.org/10.1007/s1097301546625>.
- Boerner E, Podbielska H. Application of thermal imaging to assess the superficial skin temperature distribution after local cryotherapy and ultrasound. *J Therm Anal Calorim.* 2017. <https://doi.org/10.1007/s1097301767728>.
- Podbielska H, Skrzek A. Biomedyczne zastosowania termowizji. Wrocław: Oficyna Wydawnicza Politechniki Wrocławskiej; 2014.
- Kasprzyk T, Cholewka A, Kucewicz M, Sieroń K, Sillero-Quintana M, Morawiec T, Stanek A. A quantitative thermal analysis of cyclists' thermo-active base layers. *J Therm Anal Calorim.* 2018. <https://doi.org/10.1007/s1097301877759>.
- Bauer J, Dereń E. Standaryzacja badań termograficznych w medycynie i fizykoterapii. *Acta Bio-Opt Inform Med.* 2014;20:11–20.
- Madura H. Pomiary Termowizyjne w praktyce. Warsaw: Agenda Wydawnicza PAKu; 2004.
- Dąbrowski M, Dulski R, Żmuda S, Zaborowski P. The use of thermovision camera to observe physiological and pathological conditions of oral cavity mucous membrane. *Infrared Phys Technol.* 2002;43:265–9.
- Dąbrowski M, Dulski R, Zaborowski P, Żmuda S. Study of laser irradiation thermal effect on oral tissues during procedures of dentistry. *PAK.* 2006;52(9):48–51.
- Górski J. Fizjologia człowieka. Warsaw: PZWL; 2010.
- Guyton AC, Hall JE. Textbook of medical physiology. 11th ed. Philadelphia: Elsevier Inc; 2006.
- Herman IP. Physics of the human body. New York: Springer; 2016.
- Mackowiak PA, Wasserman SS, Levine MM. A critical appraisal of 98.6 degrees F, the upper limit of the normal body temperature, and other legacies of Carl Reinhold August Wunderlich. *JAMA.* 1992;268:1578–80.
- Wendt D, van Loon L, van Marken Lichtenbelt W. Thermoregulation during exercise in the heat. *Sport Med.* 2007;37:669–82.
- Traczyk W. Fizjologia człowieka w zarysie. Warsaw: PZWL; 1989.
- Pilawski A. Podstawy biofizyki. Warsaw: PZWL; 1983.
- Górski J. Fizjologiczne podstawy wysiłku fizycznego. Warsaw: PZWL; 2008.
- Krysta L. Chirurgia szczękowo-twarzowa. Warsaw: PZWL; 1999.
- Bartkowski SB. Chirurgia szczękowo – twarzowa. Podręcznik dla studentów i lekarzy. Kraków: Collegium Medicum UJ; 1996.
- Szkarłat B, Wojtaszek-Słomińska A, Renkielska D. Kąt nachylenia zęba trzeciego trzonowego dolnego, a możliwość jego wyrznięcia - doniesienie wstępne. *Dent Forum.* 2015;1:29–33.
- Krysta L. Atlas zabiegów w chirurgii stomatologicznej. Warsaw: PZWL; 1977.
- Koczarska M. Ocena podłoża kostnego po zastosowaniu preparatu R.T.R. przed zabiegiem implantacji wszczepu środkowego. Poznań; Ph.D. thesis: Katedra i Klinika Chirurgii Stomatologicznej Uniwersytetu Medycznego im. K. Marcinkowskiego w Poznaniu; 2012. pp. 4–5.
- Ahn JJ, Shin HI. Bone tissue formation in extraction sockets from sites with advanced periodontal disease: a histomorphometric study in human. *Int J Oral Maxillofac Implants.* 2008;23:1133–8.
- Sawicki W. Histologia. Warsaw: PZWL; 2009.
- Majewski S, Majewski P. Biologiczne mechanizmy przebudowy struktur kostnych i gojenia tkanek miękkich jamy ustnej po zabiegach implantacyjnych. *Implantoprotetyka.* 2009;10:3–7.
- Fita K, Dobrzyński M, Całkosiński I, Dudek K, Bader-Orłowska D. Przydatność termografii w diagnostyce lekarsko-stomatologicznej – doświadczenia własne. *Ann Acad Med Stetin.* 2007;53:34–8.
- Kasprzyk T, Bałamut K, Kaszuba M, Kaszuba N, Stanek A, Sieroń K, Kopczyńska E, Cholewka A, Morawiec T. Zastosowanie obrazowania termicznego w stomatologii – praca pilotazowa. *Inżynier Fizyk Medyczny.* 2008;7:130–2.
- Allegrini S Jr, Koenig B Jr, Allegrini MRF, Yoshimoto M, Gedrange T, Fanghaenel J, Lipski M. Alveolar ridge sockets preservation with bone grafting: review. *Ann Acad Med Stetin.* 2008;54:70–81.

Publisher's Note Springer Nature remains neutral with regard to jurisdictional claims in published maps and institutional affiliations.